



Published By : IVAA  
the Indonesian Vascular Access Association



# Pulmonary aspergilloma presenting with recurrent hemoptysis in a patient with previously treated pulmonary tuberculosis: a case report from a rural hospital in Ketapang Regency

Herick Alvenus Willim<sup>1\*</sup>, Eva Lydia Munthe<sup>2</sup>, Widi Mujono<sup>3</sup>

<sup>1</sup>General Practitioner, Dr. Agoesdjam Regional Public Hospital, Ketapang Regency, West Kalimantan, Indonesia;

<sup>2</sup>Department of Pulmonology and Respiratory Medicine, Dr. Agoesdjam Regional Public Hospital, Ketapang Regency, West Kalimantan, Indonesia;

<sup>3</sup>Department of Radiology, Dr. Agoesdjam Regional Public Hospital, Ketapang Regency, West Kalimantan, Indonesia.

\*Corresponding to:  
Herick Alvenus Willim;  
General Practitioner, Dr. Agoesdjam Regional Public Hospital, Ketapang Regency, West Kalimantan, Indonesia;  
dr.herickalvenuswillim@gmail.com

Received: 2022-09-30  
Accepted: 2023-11-08  
Published: 2023-12-05

## ABSTRACT

**Introduction:** Pulmonary aspergilloma, also known as mycetoma or fungus ball, is a type of pulmonary aspergillosis characterized by colonizing fungi within a preexisting lung cavity, typically in previously healed tuberculosis (TB). We present a case report from a rural hospital in Ketapang Regency, Indonesia, highlighting the complexities of diagnosing and managing pulmonary aspergilloma in a patient with a history of treated pulmonary TB.

**Case Description:** A 32-year-old man with recurrent hemoptysis, fever, weight loss, and productive cough sought care after years of inconclusive tests. Despite a history of pulmonary TB and multiple negative acid-fast bacilli tests, a thorax computed tomography scan showed the presence of aspergilloma within the upper lobe of the left lung. He was given antifungal therapy. During follow-up, he continued to experience recurrent hemoptysis. Eventually, he was referred to a provincial referral hospital with cardiothoracic surgical facilities for definitive surgical management.

**Conclusion:** Pulmonary aspergilloma presents significant challenges in diagnosis and management. Recurrent or massive hemoptysis, a hallmark symptom of this condition, demands vigilant attention in patients with a history of pulmonary TB.

**Keywords:** Pulmonary aspergilloma, aspergillosis, hemoptysis, tuberculosis, surgery, resection.

**Cite This Article:** Willim, H.A., Munthe, E.L., Mujono, W. 2023. Pulmonary aspergilloma presenting with recurrent hemoptysis in a patient with previously treated pulmonary tuberculosis: a case report from a rural hospital in Ketapang Regency. *Journal of Indonesia Vascular Access* 3(2): 23-28. DOI : 10.51559/jinava.v3i2.44

## INTRODUCTION

Pulmonary diseases such as tuberculosis (TB), asthma, chronic obstructive pulmonary disease (COPD), lung cancer, and pneumonia are frequently encountered in daily clinical practice. These diseases are highly prevalent in hospitals across Indonesia. However, one pulmonary disease occurs quite frequently but is often overlooked, namely pulmonary aspergillosis. Pulmonary aspergillosis encompasses a range of conditions resulting from infections caused by fungi from the *Aspergillus* genus.<sup>1</sup> Pulmonary TB poses a substantial risk for developing pulmonary aspergillosis. Cavitary lesions after TB create an optimal environment for colonization and subsequent infection by fungi. Additionally, individuals with both human immunodeficiency virus (HIV) and TB co-infection, experiencing severe immunosuppression, are also predisposed to this condition.<sup>2</sup>

Indonesia is one of the countries with

the highest burden of TB in the world, with an estimated total TB incidence rate of 312 per 100,000 population in 2019. Indonesia has also contributed to a global increase in the number of new pulmonary TB cases, experiencing a 69% rise from 2015 to 2019.<sup>3</sup> As the number of pulmonary TB cases increases, the incidence of pulmonary aspergillosis also rises. Recent research in Indonesia indicates that 13% of patients who have completed pulmonary TB treatment develop pulmonary aspergillosis.<sup>4</sup> Therefore, vigilance towards pulmonary aspergillosis cases must be a concern.

Pulmonary aspergillosis can be divided into three broad spectrums based on the interaction between the *Aspergillus*, host immunity, and underlying lung disease: chronic pulmonary aspergillosis (CPA), allergic bronchopulmonary aspergillosis (ABPA), and invasive pulmonary aspergillosis (IPA). Among these various spectrums, CPA is the most common presentation of pulmonary

aspergillosis. CPA can present in various forms, including aspergilloma, aspergillus nodules, chronic cavitary pulmonary aspergillosis, chronic fibrosing pulmonary aspergillosis, and subacute invasive aspergillosis.<sup>5</sup> The most common type of CPA is aspergilloma (56%), followed by chronic cavitary pulmonary aspergillosis (31%).<sup>6</sup>

Aspergilloma, a fungus ball or mycetoma, is characterized by a mass of fungal hyphae, inflammatory cells, fibrin, mucus, and tissue debris. Typically, aspergilloma forms within a pre-existing cavity in the lung.<sup>7</sup> Pulmonary TB is the most common disease associated with aspergilloma. Diagnosis of aspergilloma remains a challenge, particularly in areas with limited facilities, as the clinical manifestations of pulmonary TB and aspergilloma can be similar.<sup>8</sup> A majority of pulmonary aspergilloma cases are misdiagnosed as recurrence of pulmonary TB. Awareness of pulmonary aspergilloma needs to be heightened in areas endemic

to pulmonary TB.<sup>9</sup>

In this case report, we aim to present the case of a young man with a history of previously treated pulmonary TB who has a recurrent hemoptysis, which served as the manifestation of pulmonary aspergilloma. The diagnosis and treatment can be challenging, especially in developing countries with limited hospital facilities. By gaining a deeper understanding of this frequently overlooked disease, clinicians can enhance their diagnostic accuracy and optimize treatment strategies, ultimately improving patient care and outcomes.

## CASE DESCRIPTION

A 32-year-old man from a remote district in Ketapang Regency, West Kalimantan, presented to the emergency department (ED) of Dr. Agoesdjam Regional Public Hospital with complaints of recurrent hemoptysis over the past 3 years. He also reported symptoms of intermittent fever, weight loss, decreased appetite, and productive cough. The hemoptysis worsened over the last day, with a volume of 300 ml. He has made repeated visits to the primary health care center for the previous 3 years, and acid-fast bacilli (AFB) tests on sputum samples have been performed several times with suspicion of recurrent pulmonary TB. However, the AFB test results have always been negative. He has a history of pulmonary TB with positive AFB sputum 10 years ago and has completed a 6-month TB regimen. There is no history of smoking or alcohol consumption. There is no history of cardiovascular disease, diabetes mellitus, or other significant illnesses.

On initial evaluation in ED, he was alert and fully oriented. The hemodynamic was stable with blood pressure of 120/70 mmHg, regular heart rate of 96 beats/min, respiratory rate of 20 breaths/min, body temperature of 37.2°C, and pulse oximetry saturation of 98% on room air. During lung examinations, the chest wall movement was symmetrical, and there was no tenderness or masses in the chest area. A slightly dull percussion sound and inspiratory rales were found in the left upper lung field. Another physical examination was within normal limits.

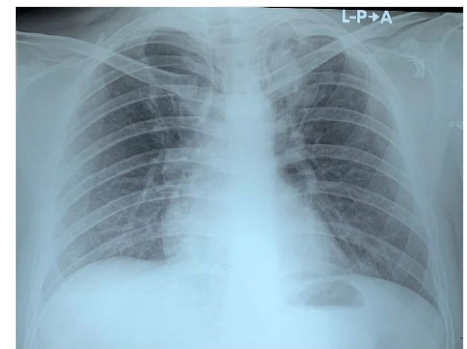
Laboratory test results showed normal leukocyte counts, slightly decreased

hemoglobin (11.9 g/dL), and slightly decreased hematocrit (36.5%), with all other parameters within normal limits. The electrocardiogram was in sinus rhythm without any abnormalities. The sputum GeneXpert test found a negative result for *Mycobacterium tuberculosis*, and the HIV test was negative as well. A chest X-ray revealed a cavitory lesion in the upper lobe of the left lung, along with a radioopaque lesion inside (Figure 1). A thorax computed tomography (CT) scan revealed a fungus ball within the cavity with an air crescent sign in the upper lobe of the left lung with a size of 3.9 x 2.8 x 3.5 cm (Figure 2). The pulmonologist and radiologist discussed and established the clinical diagnosis of pulmonary aspergilloma. The patient was then given codeine 15 mg three times a day, tranexamic acid 500 mg three times a day, and antifungal therapy with ketoconazole at a dosage of 200 mg twice a day, according to the availability of the antifungal drugs at our hospital. After three days of hospitalization, he was discharged in stable condition and scheduled for a follow-up appointment at the pulmonology outpatient clinic one week later.

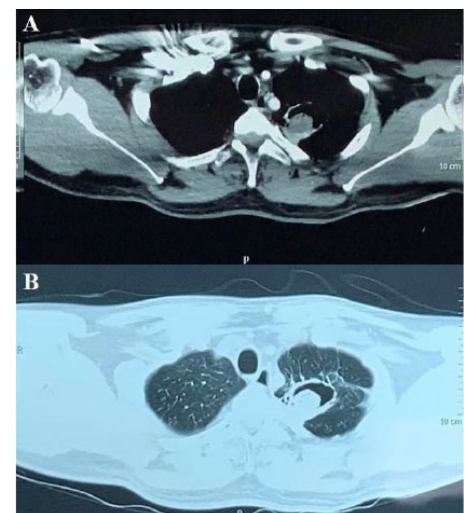
At the first follow-up visit in the outpatient clinic, he was in stable condition but still complained of recurrent hemoptysis. Antifungal treatment was continued for one month. At the second follow-up visit, a repeat chest X-ray showed a slightly reduced size of the aspergilloma (Figure 3). However, as the patient still experienced recurrent hemoptysis, we ultimately decided to refer the patient to a cardiothoracic surgeon at a provincial referral hospital in Pontianak, West Kalimantan, for further surgical consideration and management.

## DISCUSSION

The *Aspergillus* fungus, widely distributed as a saprophyte, is the causative agent for developing pulmonary aspergillomas. Typically, these growths emerge within pre-existing lung conditions, notably and frequently within previously healed TB cavities. The most common species responsible for causing aspergillosis is *Aspergillus fumigatus*, accounting for more than 90% of cases. Other species, including *Aspergillus niger*, *Aspergillus nidulans*,

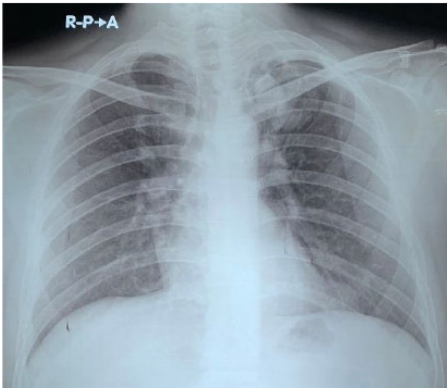


**Figure 1.** Initial Chest X-ray showed a cavitory lesion in the upper lobe of the left lung with a radioopaque lesion inside.



**Figure 2.** Axial Thorax CT scan showing a fungus ball within the cavity with an air crescent sign in the upper lobe of the left lung, measuring 3.9 x 2.8 x 3.5 cm. (A) mediastinum window; (B) lung window.

*Aspergillus terreus*, and *Aspergillus flavus*, have also been reported.<sup>10,11</sup> Occasionally, patients may not exhibit any noticeable symptoms. However, in around 75% of cases, patients may present with symptoms such as hemoptysis, chest discomfort, dyspnea, fever, weight loss, or clubbing of the fingers. Potentially fatal bleeding can occur from bronchial blood vessels, resulting from the fungus invading the vessel lining, releasing fungal toxins, or injury to the exposed blood vessels within a cavity. While aspergillomas are typically solitary, they can also appear bilaterally in the lungs.<sup>12</sup> Pulmonary aspergilloma can be classified into simple and complex



**Figure 3.** Repeat chest X-ray showing a slightly reduced size of the aspergilloma in the upper lobe of the left lung compared with the first chest X-ray

types. Simple aspergilloma manifests as an isolated cavity with thin walls enclosed by normal lung parenchyma. In contrast, complex aspergilloma manifests as thick-walled cavities associated with fibrotic lung tissue, pleural thickening, and vascular adhesions. Complex aspergilloma is typically found in the tuberculous cavity.<sup>13</sup>

In our case, the patient's clinical presentation was characterized by recurrent hemoptysis over three years, along with intermittent fever, weight loss, decreased appetite, and productive cough. Despite the patient's history of pulmonary TB a decade ago and completion of a standard TB regimen, AFB tests on sputum samples yielded consistently negative results. This emphasized the diagnostic challenge posed by patients with recurrent hemoptysis, especially those with a history of TB, as alternative etiologies may be overlooked. The delayed definitive diagnosis of pulmonary aspergilloma underscores the need for heightened clinical suspicion and more comprehensive diagnostic approaches in similar cases. Vigilance regarding cases of pulmonary aspergilloma needs to be increased, especially in countries endemic to pulmonary TB, such as Indonesia. Pulmonary aspergilloma is often misdiagnosed as recurrent pulmonary TB or pulmonary TB with smear-negative, which can inevitably delay treatment.<sup>14</sup>

A similar case has also been reported by Yaman et al., who described a 29-year-old Indonesian patient with a history of pulmonary tuberculosis experiencing

recurrent hemoptysis for 4 years. In this case, the patient was diagnosed with pulmonary aspergilloma after confirmation through a thorax CT scan and bronchoalveolar lavage (BAL) culture. The patient was subsequently managed with embolization to stop hemoptysis and antifungal therapy with variconazole. Surgical resection was not performed due to the patient's refusal.<sup>15</sup> Another similar case was reported by Nugroho et al., who described a 45-year-old Indonesian patient with pulmonary aspergilloma, a history of pulmonary tuberculosis and type 2 diabetes mellitus presenting with recurrent hemoptysis for 10 months. The patient was successfully managed by lobectomy and antifungal therapy with fluconazole.<sup>16</sup> These cases underscore the importance of vigilance for pulmonary aspergilloma in patients with a history of pulmonary TB who experience recurrent hemoptysis.

Although some patients with pulmonary aspergilloma may be asymptomatic, hemoptysis occurs in 69% to 83% of patients.<sup>17</sup> Massive (>500 mL within 24 hours) or recurrent hemoptysis is a life-threatening condition reported as the cause of death in 2% to 26% of patients with pulmonary aspergilloma.<sup>18</sup> Bleeding typically arises from arteries that supply blood to the lungs, such as the bronchial, intercostal, subclavian, axillary, or internal mammary arteries.<sup>19</sup> Bronchial arteries are the most commonly affected in hemoptysis. Therefore, bronchial artery embolization is an effective therapeutic option for managing acute hemoptysis cases in pulmonary aspergilloma, especially in cases where surgical resection is not viable. It also serves as a bridging therapy before definitive surgery.<sup>20</sup> Significant adverse outcomes resulting from bronchial artery embolization are infrequent, and immediate clinical success, marked by the cessation of hemoptysis, is typically observed at 85% to 100%. However, the recurrence rate falls from 10% to 33%.<sup>21</sup> In our case, the patient presented with recurrent hemoptysis, which is the indication for bronchial artery embolization to stop the bleeding. However, this procedure could not be performed in our case due to limitations in our hospital's facilities.

Chest X-ray is often the initial diagnostic test performed in patients presenting with lung disease. Pulmonary aspergilloma shows cavitation predominantly in the upper lobe, thickening, fibrosis, and a rounded opacity resembling a mass (fungus ball) within the cavity. Chest CT scan is the preferred imaging modality, and two typical signs can be found. The air crescent sign refers to a crescent-shaped space separating the fungus ball from the cavity wall. Monod sign, a specific sign of aspergilloma, refers to the movement-related position change of the fungus ball within the cavity and is observed in around two-thirds of patients.<sup>22</sup> The definitive diagnostic tests are serological tests for precipitins (Aspergillus IgG antibodies) or microbiological tests by culture or polymerase chain reaction using sputum or bronchoscopic specimens.<sup>23</sup> In our case, the patient did not undergo serological or microbiological tests due to limitations in our hospital facilities, so a chest X-ray and thorax CT scan supported his diagnosis of pulmonary aspergilloma.

Management of pulmonary aspergilloma remains a topic of debate. In general, asymptomatic pulmonary aspergilloma patients do not require specific treatment and can be regularly monitored, while treatment is only considered in symptomatic patients.<sup>24</sup> Although surgery continues to be the gold standard treatment for symptomatic pulmonary aspergilloma, alternative approaches are available for individuals unsuitable for surgery, those who refuse surgery, or those in areas with limited medical resources. Until now, pharmacological therapy for pulmonary aspergillosis has not achieved a favorable success rate. This is thought to be due to an avascular cavity and fungus ball, making it difficult for medications to work effectively.<sup>25</sup> Systemic azoles, the itraconazole and voriconazole, have demonstrated a success rate of 53% to 85% in treatment and are suggested as a substitute for surgery in patients with poor respiratory reserve, patient preference or when surgical treatment is unavailable.<sup>26</sup>

The recommended dosage of itraconazole by the Infectious Disease Society of America (IDSA) is 200 mg every 12 hours, while the recommended



dosage for voriconazole is 200 - 300 mg every 12 hours.<sup>27</sup> The treatment length depends on each individual's clinical status and the radiographic response, with a minimum duration of up to 6 - 12 months.<sup>28,29</sup> In our case, the patient was administered ketoconazole because we did not have itraconazole or voriconazole available. Although radiographically showing slight improvement in the size of the aspergilloma, the patient continued to experience recurrent hemoptysis clinically. As a result, the patient was referred for definitive therapy, which is surgery. We believe our patient is a good candidate for lung resection surgery to cure the aspergilloma and prevent further recurrent hemoptysis.

Systemic azoles have several drawbacks that make them unsuitable for being the primary treatment for pulmonary aspergilloma. This is due to the relatively variable success rate and a long therapy period, often exceeding six months, required to fully eliminate the infection. Additionally, cases of aspergilloma recurrence have been reported even after discontinuing the antifungal treatment. Therefore, azoles are not effective in managing patients with life-threatening hemoptysis.<sup>26</sup> Another therapeutic option to consider if systemic azoles are ineffective is the local instillation of antifungal agents into the cavity. This can be achieved through an endobronchial catheter under bronchoscopic guidance or percutaneously guided by a CT scan.<sup>30,31</sup>

The definitive treatment of pulmonary aspergilloma is surgery for patients with adequate pulmonary function. The ideal surgical approach involves an anatomical resection that includes the mycetoma and underlying cavity (a persistent cavity can lead to a risk of recurrence).<sup>32</sup> The most commonly performed procedure is lobectomy through a posterolateral thoracotomy. Precautions were exercised to avoid opening the cavity and releasing the fungal material during the surgical procedure. Parenchymal preserving lung resections such as segmentectomy and wedge resections are considered only in simple aspergilloma localized to a segment or peripherally with normal adjacent lung tissue.<sup>33</sup> Bilobectomy and pneumonectomy can be considered in cases with extensive

lesions. Cavernostomy is the choice in high-risk patients with poor functional reserves or complex aspergilloma who cannot tolerate anatomical resection.<sup>34,35</sup> Minimally invasive surgical technique using Video-Assisted Thoracoscopic Surgery (VATS) can be performed by experienced operators on patients with simple aspergilloma and selected complex aspergilloma.<sup>36</sup>

Although surgery is effective, complications can occur in around one-fifth of patients, including prolonged air leak, bleeding, empyema, wound dehiscence, pneumonia, pneumothorax, and pneumomediastinum.<sup>37,38</sup> Following surgical intervention, the likelihood of hemoptysis recurrence is low. The reported rate of pulmonary aspergilloma recurrence after surgery was 5% to 7%, primarily attributed to inadequate parenchymal resection, the presence of lung cavities, and ongoing immunosuppression.<sup>39</sup> It is essential to integrate surgical management into a multidisciplinary framework, including cardiothoracic surgeons, pulmonologists, anesthesiologists, radiologists, infectious diseases specialists, nurses, pharmacists, and physiotherapists, to address these complex patients' needs effectively.<sup>40,41</sup> Generally, the prognosis of patients with pulmonary aspergilloma undergoing surgery is favorable, with 5-year survival rates reaching 85% to 93%.<sup>42</sup> The patient in our case is a good surgical candidate and has a good prognosis if he undergoes lung resection surgery, with a higher likelihood of successful management, potential cure, and improved long-term outcomes. However, without undergoing surgery and relying solely on conservative therapy, the prognosis might be less favorable, potentially leading to ongoing symptoms, persistent, recurrent hemoptysis, lower quality of life, and an increased risk of mortality. Early surgery in patients who are good surgical candidates can result in a satisfactory outcome with minimal morbidity and mortality, effectively preventing recurrent hemoptysis, and enhancing their quality of life.<sup>43,44</sup>

While this case report provides valuable insights into the challenges of diagnosing and managing pulmonary

aspergilloma in a patient with a history of treated pulmonary tuberculosis, it has several limitations. First, the available resources and facilities in a rural hospital setting influenced the diagnostic process and treatment decisions, potentially limiting the scope of diagnostic tests and therapeutic options. Second, due to limited facilities in our hospital, the patient was referred to another hospital for surgical consideration. As a result, this case report lacks information about the outcome or specifics of the surgical intervention, thereby hindering a comprehensive evaluation of the treatment's effectiveness and long-term prognosis due to the limited follow-up duration. These limitations underscore the necessity for further studies and comprehensive case reports with longer follow-up periods to better understand the optimal management strategies for similar cases in resource-limited settings.

## CONCLUSION

Pulmonary aspergilloma presents significant challenges in diagnosis and management, particularly in patients with a history of pulmonary tuberculosis. Recurrent or massive hemoptysis, a hallmark symptom of this condition, demands vigilant clinical attention, especially in regions with a high prevalence of tuberculosis. As demonstrated in our case report, accurate diagnosis of pulmonary aspergilloma can be hindered by its resemblance to other pulmonary diseases. Management of pulmonary aspergilloma includes a range of options, from non-surgical to surgical approaches. Surgical resection of the mycetoma and the underlying cavity remains the definitive treatment. The integration of a multidisciplinary approach is paramount for comprehensive patient care. While challenges persist, advancements in diagnostic modalities and treatment strategies offer hope for improved outcomes. By raising awareness about the complexities of pulmonary aspergilloma, promoting early diagnosis, and facilitating access to appropriate therapies, we can reduce morbidity and enhance the quality of life for the patients.

## PATIENT'S INFORMED CONSENT

The patient has given informed consent regarding the publication of this case.

## FUNDING

None.

## CONFLICT OF INTEREST

The authors have no conflicts of interest to declare.

## AUTHOR CONTRIBUTION

All authors contributed equally to the writing of this manuscript.

## REFERENCES

- Jalil B, Galvis J, El Kersh K, Saad M, Fraig M, Guardiola J. Pulmonary aspergillosis: a review on diagnosis and management. *J Respir Infect*. 2018;2(2):27-34.
- Mohamed A, Obanda BA, Njeri HK, Loroyokie SN, Mashedi OM, Ouko TT, et al. Serological evidence of chronic pulmonary aspergillosis in tuberculosis patients in Kenya. *BMC Infect Dis*. 2022;22(1):1-8.
- Rozaliyani A, Rosianawati H, Handayani D, Agustin H, Zaini J, Syam R, et al. Chronic pulmonary aspergillosis in post tuberculosis patients in Indonesia and the role of Idbio aspergillus ict as part of the diagnosis scheme. *J Fungi*. 2020;6(4):1-10.
- Setianingrum F, Rozaliyani A, Syam R, Adawiyah R, Tugiran M, Sari CYI, et al. Evaluation and comparison of automated and manual ELISA for diagnosis of chronic pulmonary aspergillosis (CPA) in Indonesia. *Diagn Microbiol Infect Dis*. 2020;98(3):115124.
- Gaffney S, Kelly DM, Rameli PM, Kelleher E, Martin-Loeches I. Invasive pulmonary aspergillosis in the intensive care unit: current challenges and best practices. *APMIS*. 2023;1-14.
- Akram W, Ejaz MB, Mallhi TH, Bin Syed Sulaiman SA, Khan AH. Clinical manifestations, associated risk factors and treatment outcomes of chronic pulmonary aspergillosis (CPA): experiences from a tertiary care hospital in Lahore, Pakistan. *PLoS One*. 2021;16:1-17.
- Kousha M, Tadi R, Soubani AO. Pulmonary aspergillosis: a clinical review. *Eur Respir Rev*. 2011;20(121):156-74.
- Rajpurohit R, Wagh P, Heda M, Dubey G, Gujar PS. Prevalence of chronic pulmonary aspergillosis in fibrocavitary pulmonary tuberculosis patients. *J Fam Med Prim Care*. 2023;12(1):106-10.
- Iqbal N, Irfan M, Mushtaq A, Jabeen K. Underlying conditions and clinical spectrum of chronic pulmonary aspergillosis (CPA): an experience from a tertiary care hospital in Karachi, Pakistan. *J Fungi*. 2020;6(2):2-8.
- Alsalman J, Zaid T, Makhloq M, Madan M, Mohamed Z, Alarayedh A, et al. A retrospective study of the epidemiology and clinical manifestation of invasive aspergillosis in a major tertiary care hospital in Bahrain. *J Infect Public Health*. 2017;10(1):49-58.
- Iqbal N, Irfan M, Zubairi ABS, Jabeen K, Awan S, Khan JA. Clinical manifestations and outcomes of pulmonary aspergillosis: experience from Pakistan. *BMJ Open Respir Res*. 2016;3(1).
- Amchentsev A, Kurugundla N, Saleh AG. Aspergillus-related lung disease. *Respir Med CME*. 2008;1(3):205-15.
- El Hammoumi MM, Slaoui O, El Oueriachi F, Kabiri EH. Lung resection in pulmonary aspergilloma: experience of a Moroccan center vascular and thoracic surgery. *BMC Surg*. 2015;15(1):1-6.
- Ekeng BE, Davies AA, Osaigbovo II, Warris A, Oladele RO, Denning DW. Pulmonary and extrapulmonary manifestations of fungal infections misdiagnosed as tuberculosis: the need for prompt diagnosis and management. *J Fungi*. 2022;8(5):1-16.
- Yaman M, Sugiri J, Putra N, Santosaningsih D, Aslam A. Successful embolization in recurrent hemoptysis caused by pulmonary aspergilloma: a Case Report. *Malang Respir J*. 2023;5(1):295-303.
- Nugroho GMS, Wulandari L. Hemoptysis in a patient with pulmonary aspergilloma and type 2 diabetes mellitus: a rare case in an Indonesian adult. *Int J Surg Case Rep*. 2021;84(6):106125.
- Kokkonouzis I, Athanasopoulos I, Doulgerakis N, Tsonis G, Lampaditis I, Saridis N, et al. Fatal hemoptysis due to chronic cavitary pulmonary aspergillosis complicated by nontuberculous mycobacterial tuberculosis. *Case Rep Infect Dis*. 2011;2011:1-4.
- Ando T, Kawashima M, Masuda K, Takeda K, Okuda K, Suzuki J, et al. Exacerbation of chronic pulmonary aspergillosis was associated with a high rebleeding rate after bronchial artery embolization. *Respir Investig*. 2019;57(3):260-7.
- Shin B, Koh WJ, Shin SW, Jeong BH, Park HY, Suh GY, et al. Outcomes of bronchial artery embolization for life-threatening hemoptysis in patients with chronic pulmonary aspergillosis. *PLoS One*. 2016;11(12):1-10.
- Kaufman CS, Kwan SW. Bronchial artery embolization. *Semin Intervent Radiol*. 2022;39(3):210-7.
- Sopko DR, Smith TP. Bronchial artery embolization for hemoptysis. *Semin Interv Radiol*. 2011;28(1):48-62.
- Ofori A, Steinmetz A, Akaasi J, Frimpong G, Norman B, Obeng-Baah J, et al. Pulmonary aspergilloma: an evasive disease. *Int J Mycobacteriology*. 2016;5(2):235-9.
- Kosmidis C, Denning DW. The clinical spectrum of pulmonary aspergillosis. *Thorax*. 2015;70(3):270-7.
- Chen X, Zhou Y, Zhang L, Xu J, Liang S. The effects of antifungal therapy on the recurrence of aspergillus infection after pulmonary aspergilloma resection: a study protocol for a single-center, prospective, non-blind, randomized, 24-month, parallel group study. *BMC Pulm Med*. 2021;21(1):1-7.
- Hicham H, Rabiou S, Ibrahim I, Marouane L, Yassine O, Mohamed S. Pulmonary aspergilloma: from classification to management. *Asian Cardiovasc Thorac Ann*. 2020;28(1):33-8.
- Lang M, Lang AL, Chauhan N, Gill A. Non-surgical treatment options for pulmonary aspergilloma. *Respir Med*. 2020;164:105903.
- Patterson TF, Thompson GR, Denning DW, Fishman JA, Hadley S, Herbrecht R, et al. Practice guidelines for the diagnosis and management of aspergillosis: 2016 update by the Infectious Diseases Society of America. *Clin Infect Dis*. 2016;63(4):e1-60.
- Cadranel J, Philippe B, Hennequin C, Bergeron A, Bergot E, Bourdin A, et al. Voriconazole for chronic pulmonary aspergillosis: a prospective multicenter trial. *Eur J Clin Microbiol Infect Dis*. 2012;31(11):3231-9.
- Gupta PR, Jain S, Kewlani JP. A comparative study of itraconazole in various dose schedules in the treatment of pulmonary aspergilloma in treated patients of pulmonary tuberculosis. *Lung India*. 2015;32(4):342-6.
- Yang L, Yang C, Wan N, Xie W, Tian Y, Xiao Y, et al. Bronchoscopic instillation of amphotericin B is a safe and effective measure to treat pulmonary mycosis. *Front Pharmacol*. 2023;14:1-10.
- Denning DW, Cadranel J, Beigelman-Aubry C, Ader F, Chakrabarti A, Blot S, et al. Chronic pulmonary aspergillosis: Rationale and clinical guidelines for diagnosis and management. *Eur Respir J*. 2016;47(1):45-68.
- Nonga BN, Bang GA, Jemea B, Savom E, Yone P, Mbachou N, et al. Complex pulmonary aspergilloma: surgical challenges in a third world setting. *Surg Res Pract*. 2018;2018:1-7.
- Sameer M, David N, Rao VM, Benjamin SR, Gnanamuthu BR, Mohammad A, et al. Surgical management of pulmonary aspergilloma-12 years' experience from a tertiary care centre in India. *Indian J Thorac Cardiovasc Surg*. 2021;37(4):402-10.
- Muniappan A, Tapias LF, Butala P, Wain JC, Wright CD, Donahue DM, et al. Surgical therapy of pulmonary aspergillomas: a 30-year North American experience. *Ann Thorac Surg*. 2014;97(2):432-8.
- Moodley L, Pillay J, Dheda K. Aspergilloma and the surgeon. *J Thorac Dis*. 2014;6(3):202-9.
- Kumar A, Asaf B Bin, Puri HV, Lingaraju VC, Siddiqui S, Venkatesh PM, et al. Video-assisted thoracoscopic surgery for pulmonary aspergilloma. *Lung India*. 2017;34(4):318-23.
- Khan MA, Dar AM, Kawoosa NU, Ahangar AG, Lone GN, Bashir G, et al. Clinical profile and surgical outcome for pulmonary aspergilloma: nine year retrospective observational study in a tertiary care hospital. *Int J Surg*. 2011;9(3):267-71.
- Pihlajamaa K, Anttila VJ, Räsänen J V., Kauppi JT, Hodgson U. The fate of aspergilloma patients after surgical treatment-experience from 22 cases. *J Thorac Dis*. 2019;11(10):4298-307.

39. Garner M, Brunswicker A. Surgical management of pulmonary aspergilloma. *Shanghai Chest*. 2023;7:1-5.
40. Bongomin F. Post-tuberculosis chronic pulmonary aspergillosis: an emerging public health concern. *PLoS Pathog*. 2020;16(8):1-6.
41. Lamoth F, Calandra T. Pulmonary aspergillosis: diagnosis and treatment. *Eur Respir Rev*. 2022;31(166):1-15.
42. Kasprzyk M, Pieczyński K, Mania K, Gabryel P, Piwkowski C, Dyszkiewicz W. Surgical treatment for pulmonary aspergilloma-early and long-term results. *Kardiochirurgia i Torakochirurgia Pol*. 2017;14(2):99-103.
43. Patel DC, Bhandari P, Epstein DJ, Liou DZ, Backhus LM, Berry ME, et al. Surgical resection for patients with pulmonary aspergillosis in the national inpatient sample. *J Thorac Dis*. 2021;13(8):4977-87.
44. Ro'isah R, Anies, Sakundano M, Jazuli N. TB community empowerment model instruments in finding tuberculosis (TB) suspects. *Bali Med J*. 2022;11(2):551-4.



This work is licensed under a Creative Commons Attribution